Pleuroparenchymal Fibroelastosis

A Review of Histopathologic Features and the Relationship Between Histologic Parameters and Survival

Reena Khiroya, FRCPath, Claudio Macaluso, MD,† Maria A. Montero, MD, PhD,*‡ Athol U. Wells, MD,† Felix Chua, PhD, FRCP,† Maria Kokosi, MD,† Toby M. Maher, MD, PhD,† Anand Devaraj, MD, FRCR,‡§ Alexandra Rice, FRCPath,*‡ Elisabetta A. Renzoni, MD, PhD,†‡ and Andrew G. Nicholson, DM, FRCPath*‡*

Abstract: Pleuroparenchymal fibroelastosis (PPFE) is now a defined clinicopathologic entity in the updated 2013 ATS/ERS classification of idiopathic interstitial pneumonias (IIPs), which has led to a significant increase in cases being diagnosed at our institution. We have therefore reviewed 43 PPFE cases (58 biopsies in total) to assess whether any clinical or histopathologic features provide prognostic information. A semiquantatitive grading system was used to assess extent of fibroblastic foci, intra-alveolar fibroelastosis, visceral pleural fibrosis, chronic inflammation in areas of fibrosis, vascular fibrointimal thickening, and presence of granulomas. Other patterns of interstitial lung disease were also noted, if present. All biopsies showed intra-alveolar fibroelastosis, fibroblastic foci at the leading edge of fibrosis and chronic inflammation within areas of fibrosis, 91% showed vascular fibrointimal thickening of vessels, 73% showed pleural fibrosis, and 35% showed granulomas. Ten cases showed a coexistent IIP (5 showed usual interstitial pneumonia, 5 showed features of hypersensitivity pneumonitis). There was no significant correlation with mortality and severity of histologic parameters, other than a significant decrease in mortality in PPFE with coexistent granulomas, after adjusting for age and gender (hazard ratio, 0.27; $P=0.049$). Male gender was also associated with an increased risk of mortality, after adjusting for age (hazard ratio, 4.8; $P=0.045$). PPFE is more common than previously thought, not infrequently showing coexistent pathology, specifically usual interstitial pneumonia and granulomatous lung disease, our data suggesting the latter may have prognostic significance.

Key Words: pleuroparenchymal fibroelastosis, granulomas, idiopathic interstitial pneumonia

(*Am J Surg Pathol* 2017;41:1683–1689)

From the Departments of *Histopathology; §Radiology, Royal Brompton and Harefield NHS Foundation Trust; †Interstitial Lung Disease Unit, Royal Brompton Hospital, Imperial College; and ‡National Heart and Lung Institute, Imperial College, London, UK.

Conflicts of Interest and Source of Funding: The authors have disclosed that they have no significant relationships with, or financial interest in, any commercial companies pertaining to this article.

Correspondence: Reena Khiroya, FRCPath, Department of Histopathology, Royal Brompton and Harefield NHS Foundation Trust, Sydney Street, London SW3 6NP, UK (e-mail: reena.khiroya@doctors.org.uk).

Copyright © 2017 Wolters Kluwer Health, Inc. All rights reserved.

Initially described in Japan by Amitani et al,[1] pleuroparenchymal fibroelastosis (PPFE) has now been defined as a specific clinicopathologic entity in the updated 2013 ATS/ERS classification of idiopathic interstitial pneumonias (IIPs).[2] PPFE has characteristic imaging and histologic features,[2–4] with a predilection for the upper lobes and, on microscopy, a predominantly subpleural intra-alveolar fibrosis and elastosis (IAFE), and visceral pleural fibrosis. Patients diagnosed with PPFE may also show concurrent histologic patterns suggestive of other diseases in other lung lobes, including usual interstitial pneumonia/idiopathic pulmonary fibrosis (UIP/IPF) and hypersensitivity pneumonitis (HP).[3,4] PPFE is a disease which carries a poor prognosis, and may require lung transplantation in severe cases.[3,4]

Although subgrouped as a "rare" type of IIP,[2] its acceptance as a specific disease has led to a considerable increase in cases presenting at our institution in recent years. As such, we have noticed that the histopathologic changes of PPFE can vary in severity between different patients, but there have been no studies correlating histopathologic features with clinical survival.

Therefore, the aims of this study were to review a cohort of PPFE cases diagnosed at our institution and to assess key diagnostic histologic criteria (IAFE and visceral pleural fibrosis), as well the incidence of coexistent individual histologic patterns and individual histologic parameters. In addition, we aimed to assess if there was a relationship between histopathologic parameters and survival.

MATERIALS AND METHODS

The diagnostic pathology archives of the Royal Brompton and Harefield NHS Foundation Trust were searched for cases in which the terms "PPFE" or "pleuroparenchymal fibroelastosis" were present. The time range for the search was January 2004 to March 2017. A total of 56 cases were identified, of which 13 cases were excluded from the study as there were no slides available for review. The slides were retrieved for the remaining 43 cases and confirmed as PPFE by 3 pathologists (A.G.N., M.A.M., and R.K.), with imaging and clinical data assessed in a multidisciplinary setting to exclude other causes of IAFE such as an apical fibrous cap.

Copyright © 2017 Wolters Kluwer Health, Inc. All rights reserved.

All cases had hematoxylin and eosin–stained slides as well as Elastic van Gieson (EVG)–stained slides.

The histopathologic features of each case were assessed without knowledge of the clinical or radiologic status. A semiquantitative scoring was undertaken to evaluate the amount of fibroblastic foci at the leading edge between the fibrosis and the adjacent lung (scored semiquantitavely as 0 to 6, as undertaken in a previous study of UIP,[5] with 0 representing absence of fibroblastic foci and 6 representing the highest number of fibroblastic foci), this simplified to a 3-tiered scoring system of mild (1 and 2), moderate (3 and 4), and marked (5 and 6). Further histologic parameters assessed were: IAFE (graded as 0 = absent, 1 = mild, 2 = moderate or 3 = marked); visceral pleural fibrosis (graded as 0 = absent, 1 = mild, 2 = moderate or 3 = marked); inflammation in areas of fibrosis (graded as 0 = absent, 1 = mild if occasional inflammatory aggregates in areas of fibrosis were seen; 3 = marked if aggregates and diffuse inflammation was noted; 2 = moderate if between both), vascular fibrointimal thickening in arteries (graded as 0 = absent, 1 = mild, 2 = moderate or 3 = marked on EVG stains) vascular fibrointimal thickening in veins (graded as 0 = absent, 1 = mild, 2 = moderate or 3 = marked on EVG stains) and granulomas (absent or present). From the cohort of 43 patients, 13 patients had surgical lung biopsies from more than one lobe showing PPFE, of which 11 had biopsies from 2 sites, and 2 had biopsies from 3 sites). When more than one biopsy was assessed (1 biopsy site [n = 31], 2 [n = 9], 3 [n = 3]), histologic parameters were graded separately for each site, giving a total number of 58 biopsied sites from 43 patients. Different histologic patterns or additional histologic features in additional biopsy sites were noted.

The survival time from biopsy was calculated in months (either survival time from biopsy to March 1, 2017 if the patient was alive, or time from biopsy to date of death if the patient was deceased). In addition, from the medical records the following data were recorded for each patient if available: age in years, sex, family history of lung fibrosis, ethnicity, smoking status, and comorbidities.

Statistical analysis of the data was undertaken using STATA software (STATA data analysis software; Computing Resource Center, Santa Monica, CA). The prognostic value of histologic and clinical variables in predicting mortality was examined using Cox proportional hazards regression. Multivariate analysis was performed to determine if survival was affected by the following variables after adjusting for age (at time of biopsy) and sex: extent of fibroblastic foci, IAFE, visceral pleural fibrosis, vascular fibrointimal thickening in arteries, vascular fibrointimal thickening in veins, and the presence of granulomas, including those with a separate pattern HP (small non-necrotizing granulomas with bronchocentric inflammation, with or without focal organizing pneumonia). Multivariate analysis was also performed on those patients with a pattern of UIP and a pattern of HP excluding those with granulomas due to other causes. Statistical analysis was only performed for the 40 upper lobe biopsies, as the numbers of middle lobe and lower biopsies were too low for analysis. However, the presence of granulomas and/or a separate IIP process was included for the purposes of statistical analysis, regardless of the lobe in which they were seen.

The study was approved as a service evaluation by the Royal Brompton and Harefield NHS Foundation Trust before commencement. Some cases were previously reported in a primarily clinical study from our institution.[3]

RESULTS

Of the 43 patients with PPFE, 17 were female and 26 were male. The age range was 8 to 78 years with a mean of 55.5 years. Of 27 patients with ethnicity recorded in medical notes, 22 were white, 4 Asian, and 1 Hispanic. Smoking status was available for 36 patients, of whom 1 was a current smoker, 12 were ex-smokers and 23 were never-smokers. Of 27 patients with presence or absence of comorbidities recorded in the medical notes, 3 patients had been diagnosed and treated for respiratory infections before the diagnosis of PPFE, 2 patients had rheumatoid arthritis and 1 had pulmonary hypertension, while the remaining 21 patients had no reported comorbidities. Of 27 patients with symptoms documented at the time of diagnosis, all had reported cough and/or shortness of breath, with 3 of these patients additionally having hemoptysis. Of 34 patients for whom tuberculosis status and/or relevant microbiological tests were documented in the medical notes, none of these had a history of tuberculosis or positive microbiology results showing *Mycobacterium tuberculosis*. A total of 32 patients had CT imaging, either performed at our institution or reviewed by radiologists at our institution, with all of these patients showing radiologic features consistent with PPFE.

Of 58 biopsies from the 43 patients, there were 40 upper lobe biopsies, 4 middle lobe biopsies, and 14 lower lobe biopsies. Fifty-four biopsies were surgical lung biopsies, 2 were cryobiopsies (from 1 patient) and 2 were autopsy histology specimens (from 1 patient). Data are summarized in Table 1, with extent of fibroblastic foci grouped as mild (1, 2), moderate (3, 4), and marked (5, 6) (Figs. 1, 2). All showed IAFE (19% mild, 26% moderate, 55% marked) (Figs. 3–6), fibroblastic foci (45% mild, 36% moderate, 19% marked) (Figs. 1, 2) and chronic inflammation within areas of fibrosis (21% mild, 43% moderate, 36% marked). A degree of visceral pleural fibrosis was seen in 41 (73%) biopsies (28% mild, 25% moderate, 20% marked), while vascular fibrointimal thickening of veins was seen in 52

TABLE 1. Summary of Histopathologic Parameters of 58 Lung Biopsies Showing PPFE

	n (% Cases)			
Histopathogic Parameters	**Absent**	**Mild**	**Moderate**	**Marked**
Intra-alveolar fibroelastosis (N = 58)	0	11 (19)	15 (26)	32 (55)
Visceral pleural fibrosis (N = 58)	15 (27)	16 (28)	14 (25)	11 (20)
Fibroblastic foci (N = 58)	0	26 (45)	21 (36)	11 (19)
Inflammation in areas of fibrosis (N = 58)	0	12 (21)	25 (43)	21 (36)
Vascular fibrointimal thickening in veins (N = 57)	5 (9)	9 (16)	35 (61)	8 (14)
Vascular fibrointimal thickening in arteries (N = 56)	5 (9)	10 (18)	33 (59)	8 (14)

Copyright © 2017 Wolters Kluwer Health, Inc. All rights reserved.

Copyright © 2017 Wolters Kluwer Health, Inc. All rights reserved.

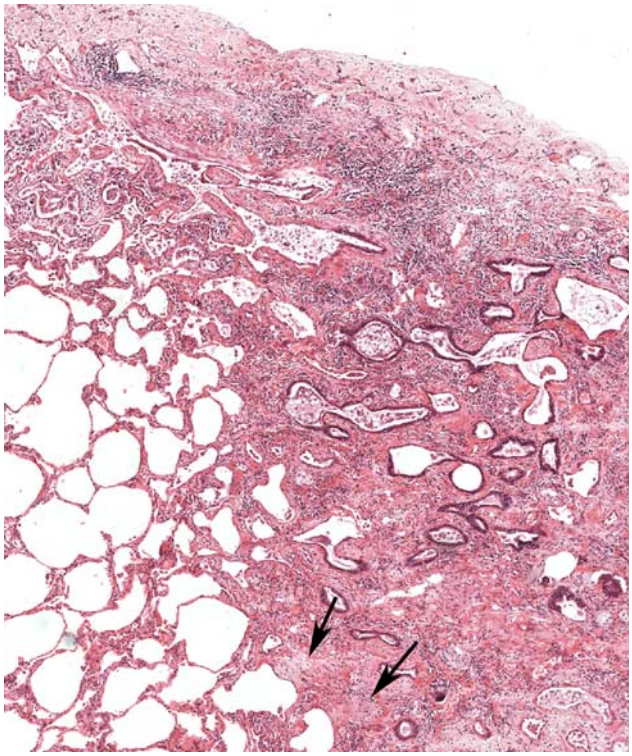

FIGURE 1. High power hematoxylin and eosin stain of PPFE showing interface of PPFE and adjacent lung, with minimal fibroblastic foci (marked with black arrows).

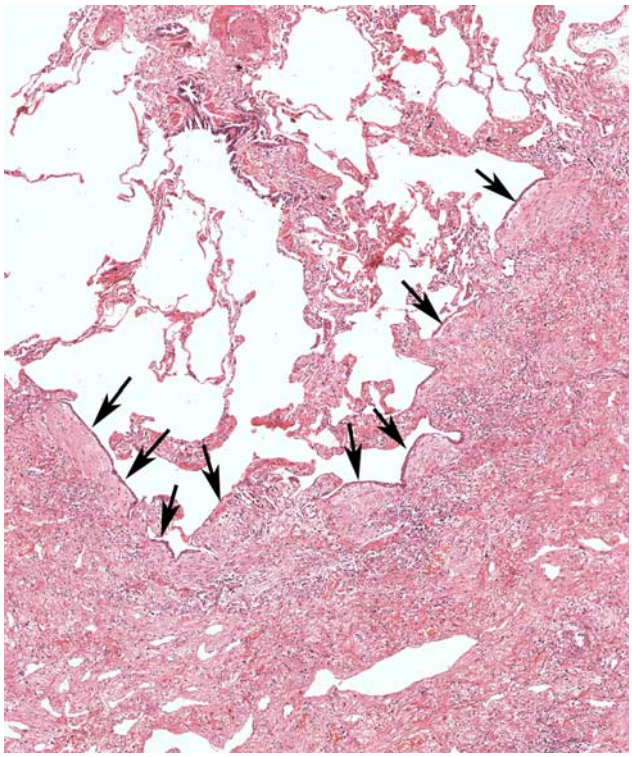

FIGURE 2. High power hematoxylin and eosin stain of PPFE showing interface of PPFE and adjacent lung, with high numbers of fibroblastic foci (marked with black arrows).

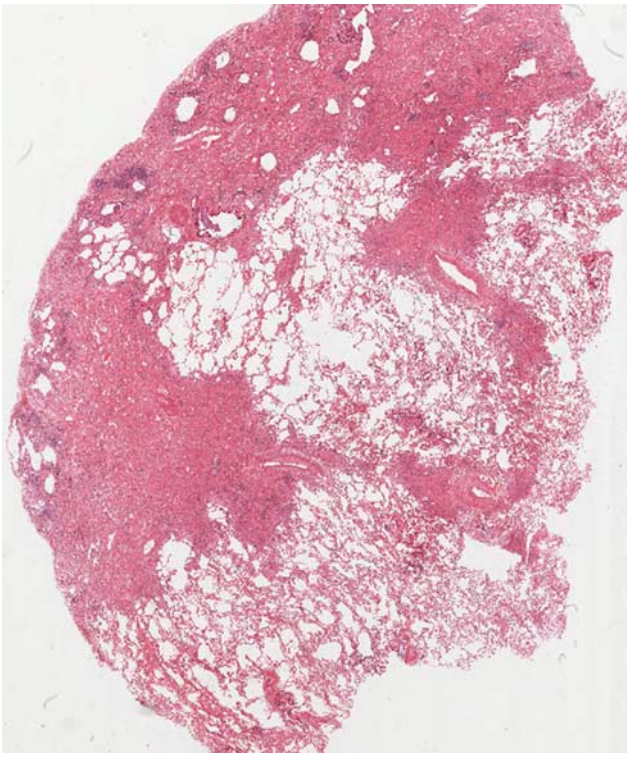

FIGURE 3. Low power histologic appearances of PPFE. Hematoxylin and eosin stain shows subpleural fibroelastosis which focally extends into lung parenchyma.

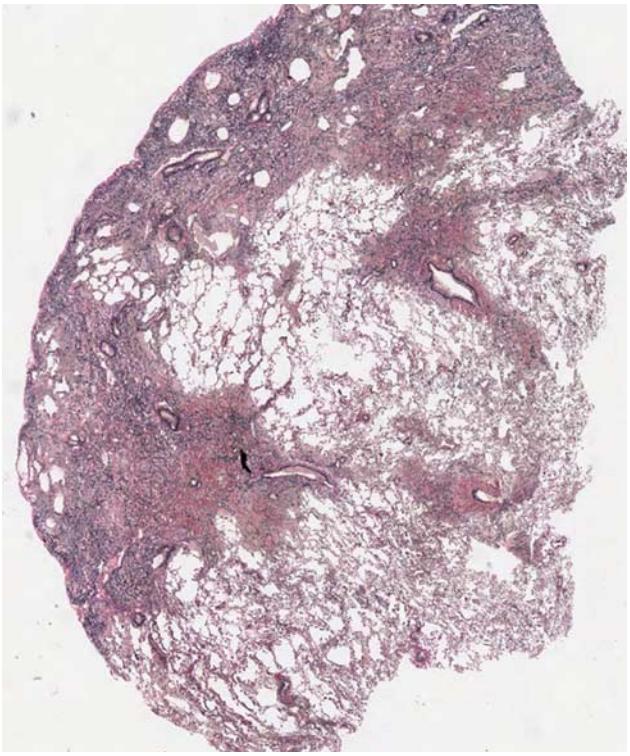

FIGURE 4. Low power histologic appearances of PPFE. EVG stain shows increase in subpleural elastin fibers.

Copyright © 2017 Wolters Kluwer Health, Inc. All rights reserved.

Copyright © 2017 Wolters Kluwer Health, Inc. All rights reserved.

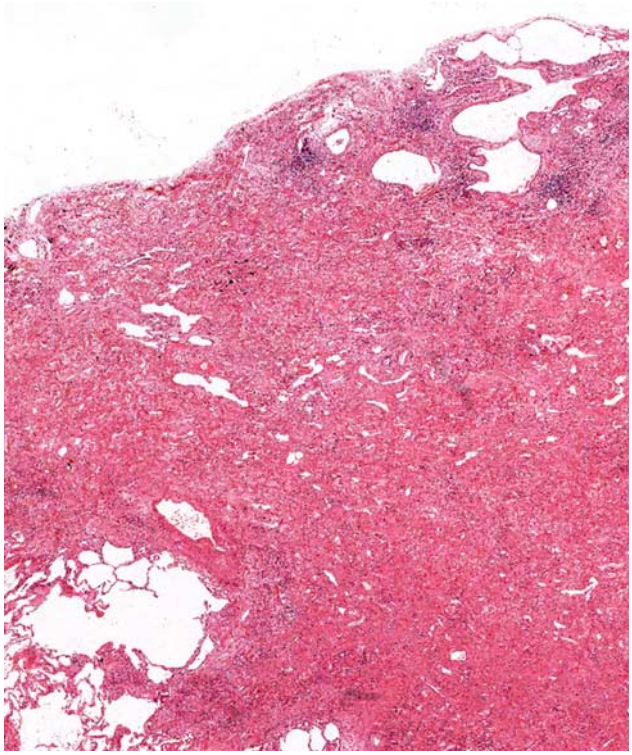

FIGURE 5. High power histologic appearance of PPFE. Hematoxylin and eosin stain shows marked subpleural fibroelastosis.

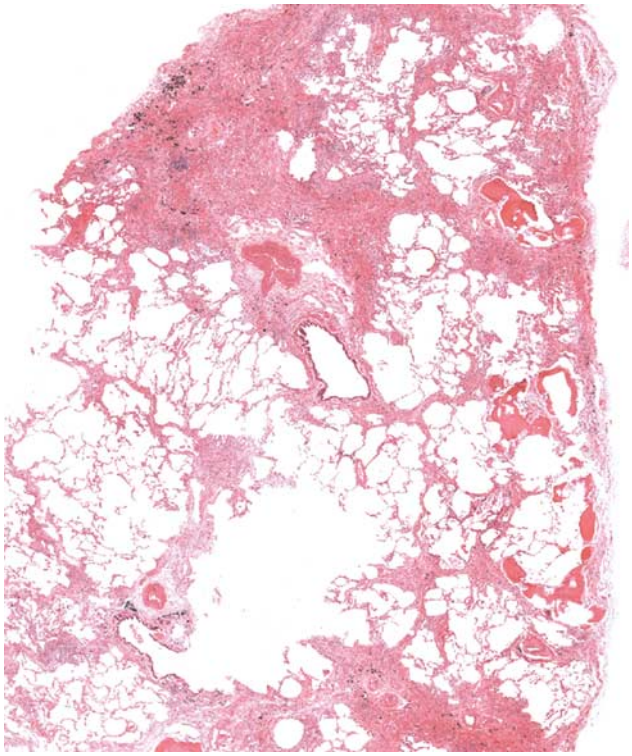

FIGURE 7. Low power hematoxylin and eosin stain showing usual interstitial pneumonia with subpleural and paraseptal fibrosis and fibroblastic foci.

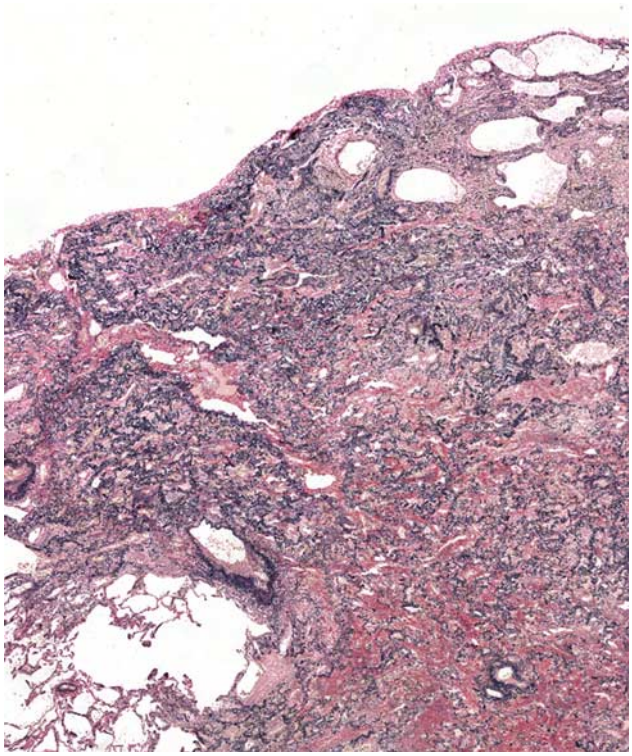

FIGURE 6. High power histologic appearances of PPFE. EVG stain shows characteristic network of elastin fibers.

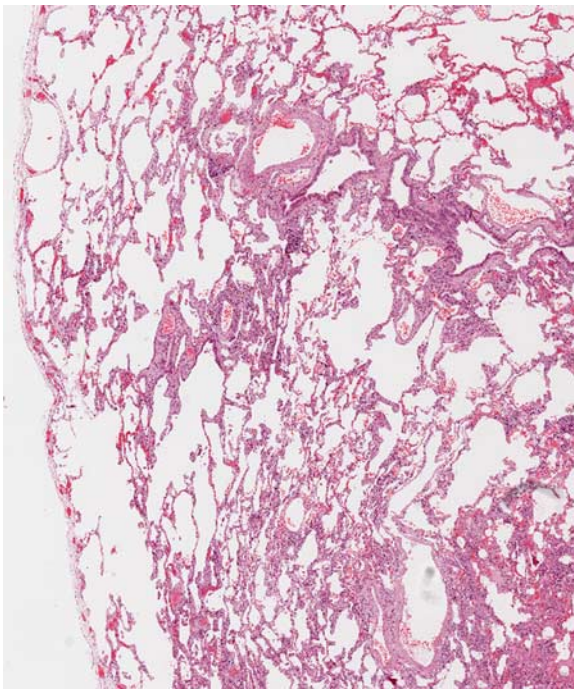

FIGURE 8. Low power hematoxylin and eosin stain showing pattern of hypersensitivity pneumonitis seen in separate lobe to PPFE. Hypersensitivity pneumonitis shows bronchocentric pattern of inflammation and loose granulomas (Fig. 9).

Copyright © 2017 Wolters Kluwer Health, Inc. All rights reserved.

Copyright © 2017 Wolters Kluwer Health, Inc. All rights reserved.

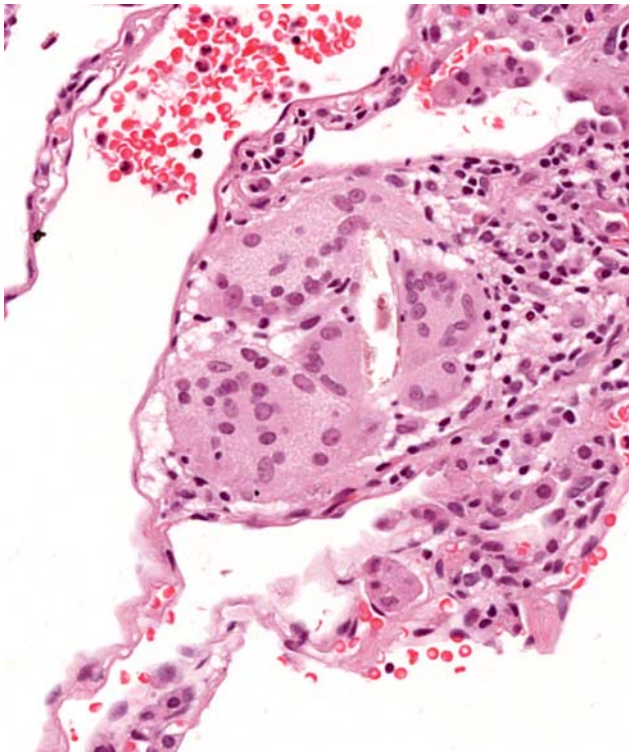

FIGURE 9. High power hematoxylin and eosin stain. Loose nonnecrotizing granuloma seen in hypersensitivity pneumonitis.

(91%) biopsies (16% mild, 61% moderate, 14% marked) and fibrointimal vascular thickening of arteries was seen in 51 (91%) biopsies (18% mild, 51% moderate, 14% marked).

Of the 43 patients, 15 (35%) showed other histopathologic features within the same lobe as PPFE, with 15 patients (35%) having granulomas, 1 patient having an aspergilloma (2%), and 2 patients (4%) with vasculitis, 1 in the lung biopsy (granulomatosis with polyangiitis [Wegener's granulomatosis]), and 1 with a known diagnosis of ANCA-positive renal vasculitis. Ten patients showed a different pattern of interstitial lung disease in a separate lobe to the PPFE biopsies, with 5 patients (12%) showing a UIP pattern (Fig. 7) and 5 (12%) showing features of HP (Figs. 8, 9). None of the patients with features of HP showed areas with a UIP pattern.

Survival data were available for 42 of 43 patients. Of these, 27 were alive (64.3%) and 15 patients (35.7%) were deceased. The mean survival time following the biopsy diagnosis of PPFE was 29.6 months with a mean follow-up of 32.9 months (range: 1 to 123 mo) (the patient with only 1 month follow-up died within a month from biopsy).

Multivariate Cox proportional hazards regression analysis showed that male sex was a predictor of increased risk of mortality after adjusting for age (hazard ratio, 5.31; $P=0.04$; 95% confidence interval, 1.08-26.12). As summarized in Table 2, multivariate Cox proportional hazards regression analysis adjusting for age and gender, showed that the presence of granulomas in any lobe, was associated with a statistically significant decrease in risk of mortality (hazard ratio, 0.27; $P=0.049$; confidence interval, 0.07-0.99). Extent of fibroblastic foci, IAFE, visceral pleural fibrosis, inflammation in areas of fibrosis, vascular fibrointimal thickening in arteries and vascular fibrointimal thickening in veins were not associated with a significant effect on mortality after adjusting for age and gender. In the 36 patients with available smoking history, multivariate Cox proportional hazards regression analysis showed that presence of granulomas, when adjusted for sex, age at time of biopsy, and smoking status, was still significantly protective against mortality (hazard ratio, 0.25; $P=0.05$; confidence interval, 0.07-0.97). The presence of a separate histologic pattern of UIP or HP in any lobe did not show a statistically significant effect on mortality.

DISCUSSION

This study confirms that PPFE is an aggressive disease within the idiopathic IIPs, appears more common than previously thought, and that around 25% of cases show features indicating likely coexistent clinicopathologic disorders, specifically UIP/IPF and HP.

While PPFE was viewed as rare before being added to the idiopathic IIPs in 2013,[2] increased awareness of its existence has prompted a significant increase in publications of both idiopathic PPFE and PPFE due to secondary causes and associations,[4,6–23] suggesting that the disease is not as rare as initially thought.

The literature since 2013 has also reported additional cases where there are coexistent interstitial lung diseases in other lobes,[3,4,14] predominantly UIP/IPF but also cases suggestive of HP.[3] In our series, the incidence was 25% overall (half with a histologic pattern of UIP and half with HP), which is lower than other series reporting 43%

TABLE 2. Proportional Hazards Regression Analysis of Survival Based on Histopathologic Data

Variable(s) Analyzed, All Hazard Ratios Adjusted for Age and Sex	Hazard Ratio	*P*	95% Confidence Interval	No. Patients
Fibroblastic foci, upper lobe biopsies	0.87	0.4	0.61-1.24	40
Inflammation, upper lobe biopsies	0.57	0.38	0.2-2.0	40
Vascular fibrointimal thickening in arteries, upper lobe biopsies	1.3	0.5	0.6-2.9	40
Vascular fibrointimal thickening in veins, upper lobe biopsies	2.2	0.1	0.85-5.9	40
Visceral pleural thickening, upper lobe biopsies	1.2	0.4	0.75-1.96	40
Intra-alveolar fibroelastosis, upper lobe biopsies	1.2	0.4	0.5-2.6	40
Presence of granulomas in any lobe	0.27	0.049	0.07-0.99	42
Presence of separate IIP in any lobe	0.56	0.39	0.16-2.04	41
Presence of usual interstitial pneumonia, in any lobe	0.77	0.73	0.16-3.62	41
Presence of hypersensitivity pneumonitis, in any lobe	0.44	0.43	0.05-3.43	41

Copyright © 2017 Wolters Kluwer Health, Inc. All rights reserved.

Copyright © 2017 Wolters Kluwer Health, Inc. All rights reserved.

and 75%.[3,4,24] In the 10 cases with coexistent idiopathic IIP in this study, the presence of UIP or HP did not significantly affect mortality, although the number of cases for statistical analysis (5 UIP and 5 HP) was low.

This study also provided an opportunity to assess whether the extent of histologic parameters in PPFE provided potentially useful prognostic or etiologic data. In particular, we looked at whether fibroblastic proliferation at the leading edge of the fibrosis correlated with mortality, as has been shown in several, though not all, studies of UIP/IPF.[5,25–27] Our data showed no correlation, a finding which supports the pathogenesis of PPFE being different to UIP. We emphasize that we use the term UIP herein in the context of a histologic pattern not limited to UIP/IPF because, although a histologic pattern of UIP is most commonly seen in patients with IPF, a small proportion of patients will have chronic HP. Indeed, many cases of PPFE have a history of previous infection and morphologically, the pattern of IAFE appears more that of an organizing pneumonia that has "petrified" rather than resolved.

When we assessed other features, we found that the presence of granulomas was significantly associated with a decreased risk of mortality, after adjusting for gender, age at time of biopsy and smoking status. Of these 15 patients, only 5 showed other interstitial features suggestive of HP and the presence of PPFE/HP alone was not associated with a statistically significant decreased risk of mortality. Of the 5 patients with granulomas and HP features, there were 2 with high *Aspergillus sp.* precipitins, one was found to have a coexistent *Mycobacterium avium-intracellulare* infection and 1 had IgA deficiency. Of the remaining 10 patients with granulomas, 1 had a coexistent aspergilloma and 2 had coexistent vasculitis. This supports the authors' hypothesis that, in some cases, PPFE might represent a progressive fibrosing immune-mediated response to identified or unidentified infection,[3] inhaled antigen or allergen and that the presence of granulomas may be a marker of such cases. This hypothesis is supported by a study of alveolar fibroelastosis after lung and stem cell transplantation in which a nonspecific fibrin-rich reaction to injury failed to resolve with progression toward IAFE.[28] In addition, given there is also vascular fibrointimal thickening, vascular damage could also play some role in the pathogenic process of PPFE, although a potential mechanism remains unknown.

In relation to clinical data, we also found that male gender was a predictor of increased risk of mortality in our cohort after adjusting for age. This has not been reported and may provide new prognostic information about PPFE. Also, 2 patients in our study had a family history of pulmonary fibrosis. The first of these patients had 6 relatives (first degree, second degree, and third degree) who died following pulmonary fibrosis, the second whose mother also had PPFE. This supports the possibility of an underlying genetic cause in these rare familial cases of PPFE, with previous familial cases also reported.[29,30]

Following the introduction of transbronchial cryobiopsy for the diagnosis of interstitial lung diseases at our institution, one case of PPFE in this study was diagnosed using this technique. Cryobiopsy is a less invasive procedure which offers advantages with regards to decreased risk and complications versus surgical lung biopsy.[31–37] However, due to the transbronchial method of sampling, the pleura was not included in these samples, so multidisciplinary discussion with review of imaging findings was essential. Indeed, multidisciplinary discussion is equally important in cases diagnosed on surgical lung biopsy, as IAFE is not specific to PPFE, also being seen in apical caps, reaction to radiotherapy, drug reactions and inhalational injuries such as paraquat.[38] Of note, some cases have even been diagnosed on transbronchial biopsy.[9] The relevance of sampling, tissue volume and multidisciplinary review is emphasized by the fact that visceral pleural fibrosis was only seen in 73% of the biopsies with PPFE, in that a diagnosis of PPFE can be made without this feature in the biopsies if clinical and imaging data support the diagnosis.

We recognize that our study has limitations. Because of its retrospective nature, we did not have complete clinical history and smoking status data for all patients. Furthermore, the number of cases included in the study was low for the purposes of statistical analysis. We also recognize that, whilst a histologic pattern of UIP is most commonly seen in patients with IPF, a minority of patients will have chronic HP. To this end, we have avoided calling patients with a pattern of UIP as UIP/IPF and limited classification of HP to those biopsies with separate areas showing features of typically subacute disease (small non-necrotizing granulomas, bronchocentric inflammation with or without focal organizing pneumonia). Indeed, it is notable that one publication proposes that UIP/PPFE is a separate entity to UIP/IPF, although more studies of patients with multiple patterns are needed.[21] Despite the above, we still feel that our data are reasonably robust, and comprise the largest histologic series of PPFE cases to date.

In conclusion, PPFE is more common than previously thought; not infrequently showing coexistent pathology, specifically UIP and granulomatous lung disease, our data suggesting the latter may have prognostic significance.

ACKNOWLEDGMENTS

The authors would like to thank Dr Huzaifa Adamali, Dr Andrew Kyoong, Professor Prue Russell, Dr Myriam Remmelink, Dr Paul de Vuyst, and Dr Simon Trotter who provided us with updated clinical data for the patients in this study.

REFERENCES

1. Amitani R, Niimi A, Kuse F. Idiopathic pulmonary upper lobe fibrosis (IPUF). *Kokyu*. 1992;11:693–699.
2. Travis WD, Costabel U, Hansell DM, et al. An official American Thoracic Society/European Respiratory Society statement: update of the international multidisciplinary classification of the idiopathic interstitial pneumonias. *Am J Respir Crit Care Med*. 2013;188:733–748.
3. Reddy TL, Tominaga M, Hansell DM, et al. Pleuroparenchymal fibroelastosis: a spectrum of histopathological and imaging phenotypes. *Eur Respir J*. 2012;40:377–385.

Copyright © 2017 Wolters Kluwer Health, Inc. All rights reserved.

Copyright © 2017 Wolters Kluwer Health, Inc. All rights reserved.

4. Nakatani T, Arai T, Kitaichi M, et al. Pleuroparenchymal fibroelastosis from a consecutive database: a rare disease entity? *Eur Respir J*. 2015;45:1183–1186.
5. Nicholson AG, Fulford LG, Colby TV, et al. The frequency of fibroblastic foci in usual interstitial pneumonia and their relationship to disease progression. *Am J Respir Crit Care Med*. 2002;166: 173–177.
6. Gomes PS, Shiang C, Szarf G, et al. Pleuroparenchymal fibroelastosis: report of two cases in Brazil. *J Bras Pneumol*. 2017;43:72–75.
7. Baroke E, Heussel CP, Warth A, et al. Pleuroparenchymal fibroelastosis in association with carcinomas. *Respirology*. 2016;21: 191–194.
8. Esteves C, Costa FR, Redondo MT, et al. Pleuroparenchymal fibroelastosis: role of high-resolution computed tomography (HRCT) and CT-guided transthoracic core lung biopsy. *Insights Imaging*. 2016;7:155–162.
9. Kushima H, Hidaka K, Ishii H, et al. Two cases of pleuroparenchymal fibroelastosis diagnosed with transbronchial lung biopsy. *Respir Med Case Rep*. 2016;19:71–73.
10. Mariani F, Gatti B, Rocca A, et al. Pleuroparenchymal fibroelastosis: the prevalence of secondary forms in hematopoietic stem cell and lung transplantation recipients. *Diagn Interv Radiol*. 2016;22:400–406.
11. Sato S, Hanibuchi M, Takahashi M, et al. A patient with idiopathic pleuroparenchymal fibroelastosis showing a sustained pulmonary function due to treatment with pirfenidone. *Intern Med*. 2016;55:497–501.
12. Thangakunam B, Isaac BT, Christopher DJ, et al. Idiopathic pleuroparenchymal fibroelastosis—a rare idiopathic interstitial pneumonia. *Respir Med Case Rep*. 2016;17:8–11.
13. Yoshida Y, Nagata N, Tsuruta N, et al. Heterogeneous clinical features in patients with pulmonary fibrosis showing histology of pleuroparenchymal fibroelastosis. *Respir Investig*. 2016;54:162–169.
14. Hirota T, Yoshida Y, Kitasato Y, et al. Histological evolution of pleuroparenchymal fibroelastosis. *Histopathology*. 2015;66:545–554.
15. Huang Z, Li S, Zhu Y, et al. Pleuroparenchymal fibroelastosis associated with aluminosilicate dust: a case report. *Int J Clin Exp Pathol*. 2015;8:8676–8679.
16. Portillo K, Guasch I, Becker C, et al. Pleuroparenchymal fibroelastosis: a new entity within the spectrum of rare idiopathic interstitial pneumonias. *Case Rep Pulmonol*. 2015;2015:810515.
17. Takeuchi Y, Miyagawa-Hayashino A, Chen F, et al. Pleuroparenchymal fibroelastosis and non-specific interstitial pneumonia: frequent pulmonary sequelae of haematopoietic stem cell transplantation. *Histopathology*. 2015;66:536–544.
18. Beynat-Mouterde C, Beltramo G, Lezmi G, et al. Pleuroparenchymal fibroelastosis as a late complication of chemotherapy agents. *Eur Respir J*. 2014;44:523–527.
19. Chen F, Matsubara K, Miyagawa-Hayashino A, et al. Lung transplantation for pleuroparenchymal fibroelastosis after chemotherapy. *Ann Thorac Surg*. 2014;98:e115–e117.
20. Fujikura Y, Kanoh S, Kouzaki Y, et al. Pleuroparenchymal fibroelastosis as a series of airway complications associated with chronic graft-versus-host disease following allogeneic bone marrow transplantation. *Intern Med*. 2014;53:43–46.
21. Oda T, Ogura T, Kitamura H, et al. Distinct characteristics of pleuroparenchymal fibroelastosis with usual interstitial pneumonia compared with idiopathic pulmonary fibrosis. *Chest*. 2014;146: 1248–1255.
22. Hirota T, Fujita M, Matsumoto T, et al. Pleuroparenchymal fibroelastosis as a manifestation of chronic lung rejection? *Eur Respir J*. 2013;41:243–245.
23. Ofek E, Sato M, Saito T, et al. Restrictive allograft syndrome post lung transplantation is characterized by pleuroparenchymal fibroelastosis. *Mod Pathol*. 2013;26:350–356.
24. Cheng SK, Chuah KL. Pleuroparenchymal fibroelastosis of the lung: a review. *Arch Pathol Lab Med*. 2016;140:849–853.
25. Flaherty KR, Colby TV, Travis WD, et al. Fibroblastic foci in usual interstitial pneumonia: idiopathic versus collagen vascular disease. *Am J Respir Crit Care Med*. 2003;167:1410–1415.
26. Enomoto T, Kawamoto M, Kunugi S, et al. Clinicopathological analysis of patients with idiopathic pulmonary fibrosis which became acutely exacerbated after video-assisted thoracoscopic surgical lung biopsy. *Nihon Kokyuki Gakkai Zasshi*. 2002;40:806–811.
27. King TE Jr, Schwarz MI, Brown K, et al. Idiopathic pulmonary fibrosis: relationship between histopathologic features and mortality. *Am J Respir Crit Care Med*. 2001;164:1025–1032.
28. Jonigk D, Rath B, Borchert P, et al. Comparative analysis of morphological and molecular motifs in bronchiolitis obliterans and alveolar fibroelastosis after lung and stem cell transplantation. *J Pathol Clin Res*. 2017;3:17–28.
29. Azoulay E, Paugam B, Heymann MF, et al. Familial extensive idiopathic bilateral pleural fibrosis. *Eur Resp J*. 1999;14:971–973.
30. Frankel SK, Cool CD, Lynch DA, et al. Idiopathic pleuroparenchymal fibroelastosis: description of a novel clinicopathologic entity. *Chest*. 2004;126:2007–2013.
31. Ussavarungsi K, Kern RM, Roden AC, et al. Transbronchial cryobiopsy in diffuse parenchymal lung disease: retrospective analysis of 74 cases. *Chest*. 2017;151:400–408.
32. Tomassetti S, Wells AU, Costabel U, et al. Bronchoscopic lung cryobiopsy increases diagnostic confidence in the multidisciplinary diagnosis of idiopathic pulmonary fibrosis. *Am J Respir Crit Care Med*. 2016;193:745–752.
33. Sharp C, McCabe M, Adamali H, et al. Use of transbronchial cryobiopsy in the diagnosis of interstitial lung disease-a systematic review and cost analysis. *QJM*. 2017;110:207–214.
34. Ravaglia C, Bonifazi M, Wells AU, et al. Safety and diagnostic yield of transbronchial lung cryobiopsy in diffuse parenchymal lung diseases: a comparative study versus video-assisted thoracoscopic lung biopsy and a systematic review of the literature. *Respiration*. 2016;91:215–227.
35. Hagmeyer L, Theegarten D, Wohlschlager J, et al. The role of transbronchial cryobiopsy and surgical lung biopsy in the diagnostic algorithm of interstitial lung disease. *Clin Respir J*. 2016;10:589–595.
36. Colby TV, Tomassetti S, Cavazza A, et al. Transbronchial cryobiopsy in diffuse lung disease: update for the pathologist. *Arch Pathol Lab Med*. 2017;141:891–900.
37. Casoni GL, Tomassetti S, Cavazza A, et al. Transbronchial lung cryobiopsy in the diagnosis of fibrotic interstitial lung diseases. *PLoS One*. 2014;9:e86716.
38. Corrin B, Nicholson A G. *Acute Alveolar Injury and Repair Pathology of the Lungs*, 3rd ed. Edinburgh: Elsevier; 2011:135–154.

Copyright © 2017 Wolters Kluwer Health, Inc. All rights reserved.

Copyright © 2017 Wolters Kluwer Health, Inc. All rights reserved.